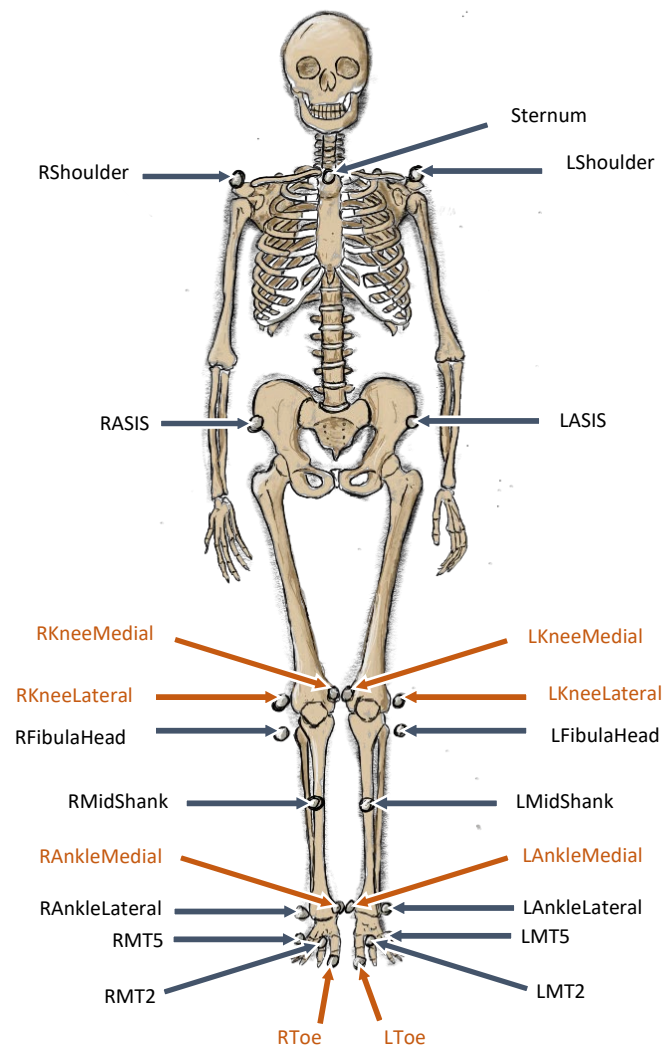


■ Tracking Markers

■ Static Only Markers

### Front



Marker Name	Marker location
<b>LShoulder</b>	Left Acromion process
<b>RShoulder</b>	Right Acromion process
<b>Sternum</b>	Sternal notch
<b>LASIS</b>	Left Anterior Superior Iliac Spine
<b>RASIS</b>	Right Anterior Superior Iliac Spine
<b>LPSIS</b>	Left Posterior Superior Iliac Spine
<b>RPSIS</b>	Right Posterior Superior Iliac Spine
<b>LKneeMedial</b>	Left Medial Femoral Epicondyle
<b>LKneeLateral</b>	Left Lateral Femoral Epicondyle
<b>RKneeMedial</b>	Right Medial Femoral Epicondyle
<b>RKneeLateral</b>	Right Lateral Femoral Epicondyle
<b>LFibulaHead</b>	Left Head of Fibula
<b>RFibulaHead</b>	Right Head of Fibula
<b>LMidShank</b>	Located anterior medial aspect of the left tibia, mid-shank
<b>RMidShank</b>	Located anterior medial aspect of the right tibia, mid-shank
<b>LAnkleMedial</b>	Left Medial Ankle Malleolus
<b>LAnkleLateral</b>	Left Lateral Ankle Malleolus
<b>RAnkleMedial</b>	Right Medial Ankle Malleolus
<b>RAnkleLateral</b>	Right Lateral Ankle Malleolus
<b>LHeel</b>	Left calcaneus
<b>RHeel</b>	Right calcaneus
<b>LToe</b>	Top of the most distal part of first phalanx of left foot
<b>RToe</b>	Top of the most distal part of first phalanx of right foot
<b>LMT2</b>	Top of the head of the second metatarsal of the left foot
<b>RMT2</b>	Top of the head of the second metatarsal of the right foot
<b>LMT5</b>	Top of the head of the fifth metatarsal of the left foot
<b>RMT5</b>	Top of the head of the fifth metatarsal of the right foot

### Back

